

Norbert Schrage (1) , Markus Frenz (2), F. Spöler (3), Michael Forst (3) Kurz (3)
 (1) Dept.- of Ophthalmology, Cologne Merheim, Germany; (2) Aachen Center of Technologytransfer in Ophthalmology (ACTO), Aachen, Germany; (3) Institute of Semiconductors at the RWTH Aachen, Germany

Abstract

Introduction: Ocular burns are via high resolution OCT technique now real time follow up events. Therefore we evaluated HF burns treated and untreated to learn on the efficacy of decontamination fluids usually recommended for HF burns. **Methods:** Ex vivo eyes of slaughtered rabbits were exposed to 25 ul of 1,25 mol HF filter paper. After removing the filter no rinsing or immediate rinsing with water, calcium gluconate 1% or Hexafluorine® (Anti HF) solution from Prevor started for 15 min., continuous OCT observation was done during 75 min. **Results:** there was total penetration of the untreated corneas within 15 min, water rinsing resulted in deep stromal changes with less severity, calcium gluconate showed initial stop of burn but later progression Hexafluorine® solution proofed to stop burn without any progression after 75 min. There was corneal opacity for water, calcium gluconate and no treatment, only Hexafluorine® corneas remained clear. **(1)Conclusion:** There is significant difference in decontamination of HF from ocular tissue dependent on the type of rinsing fluid. Rinsing with water is better than no treatment, significant improvement is done by calcium gluconate rinsing but best results were found with Hexafluorine® solution. The mechanism of decontamination is now directly accessible via OCT and comparisons of rinsing fluids are possible.

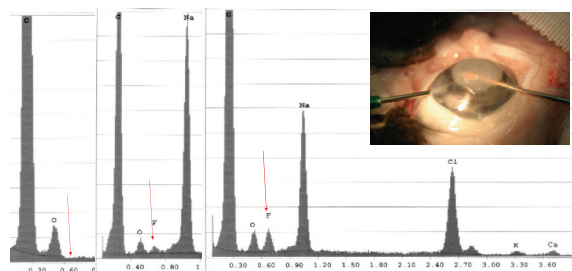


Fig. 1: penetration of HF into the eye measured by withdrawn aqueous humor (inset) and energy dispersive X-ray analysis. Left no F in the aqueous humor, after one minute first F and after 2 minutes considerable high concentrations of F within the anterior chamber

Introduction:

HF burn of the eye are devastating and dangerous. All tissue Calcium and Magnesium are directly precipitated to CaF_2 or MgF_2 . Thus there is a sudden tissue necrosis and propagating of free fluor within the tissue. We tried to have a close look on the actual therapeutic regimens, which are proposed to treat corneal burns. There are mainly three recommendations from simple water rinsing (2) to more qualified calciumgluconate 1% rinsing (4) up to the new recommendation of initial rinsing with Hexafluorine® solution (3)

We focussed on the morphological appearance of precipitation of calcium-magnesium molecules in reaction with fluor. Therefore our primary goal was to have insight in the action of calciumgluconate and Hexafluorine® solution in combination with HF. Thus we performed experiments within beakers and on the eEx vivo Eye irritation assay in combination with high resolution OCT analysis of the corneas exposed to HF and rinsing solutions.

Materials and Methods:

Experimental beaker:

Different amounts from 100 to 10 ul 48% HF solution was mixed to amounts of 900 to 990 ul AntiHF solution. The opacity of the fluid is observed when additional CaCl_2 solution is added. Thus we have an answer on the chemical type of amphoteric action of AntiHF solution, keeping the F molecule trapped and the CaCl_2 free in the watery surrounding. We confirm by this experiment the producers (Prevor) explanation of the action of AntiHF solution.

Experimental rinsing on Ex Vivo Eye Irritation Test , (EVEIT) isolated rabbit eyes:

1. Diffusion experiments

Anterior chamber of a rabbit eye is cannulated and a burn with 2,5 % HF solution is performed. Samples of the aqueous humor were withdrawn and the samples were dried, sputtered with elemental carbon and analysed by means of energy dispersive X-ray analysis on the occurrence of Fluor. Samples were taken before application of HF, 1 min and 2 min after exposure with HF solution.

2. Rinsing experiments

Rabbit corneas were exposed to 20 ul of 2,5% H. Each 3 corneas were treated without any rinsing, or 15 min of rinsing with tap water, 1% calciumgluconate or AntiHF solution respectively. Directly before burns with HF, directly after removal of the HFsoaked filter paper and directly after stop of rinsing with the special fluids (at 15 min) and after 75 minutes we took high resolution OCT images and conventional photographs of the corneas.

Results:

Experimental beaker:

Fig. 2a-d show the disappearance of the precipitates within the fluids indicating that HF is kept trapped by amphoteric forces of the AntiHF solution.

Diffusion experiments:

The Appearance of fluor in the anterior chamber is early and of high concentration it is coincident with a dramatic decrease of Na in the anterior chamber fluid.

Rinsing experiments:

In rinsing experiments the corneas shrink considerably with or without rinsing. There is a slower Process of shrinkage (Fig. 3 a-c) in case of no rinsing, tap water rinsing or calcium gluconate rinsing. The Hexafluorine® rinsed eyes shrink directly during the initial rinsing. The optical density of the corneal stroma ins changing dramatically in water and calciumgluconate rinsed eyes corneas rinsed with Hexafluorine® stay nearby completely clear up to the end of the experiment. Fig. 3d

Type of amphoteric action on HF




Fig. 2. The type of amphoteric action of Hexafluorine® (Anti-HF®): HF + saturated CaCl_2 solution will result in turbidity of fluid. If amphoteric binding of Hexafluorine® (Anti-HF®) is stronger than CaF_2 binding, than clear fluid should result. Thus addition of amounts of Hexafluorine® were given to the said solutions and in 10 ul of 48% HF (Fig. 2a-d) added with 990 ul Hexafluorine® solution we found clear fluid indicating complete amphoteric binding of the HF.

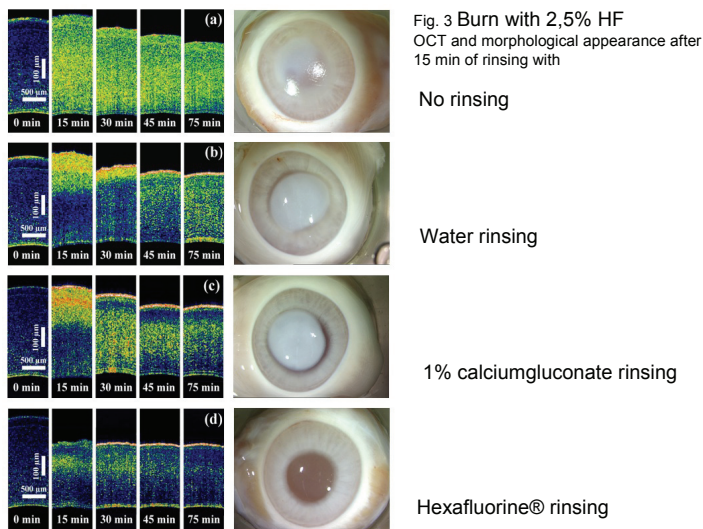


Fig. 3 Burn with 2,5% HF OCT and morphological appearance after 15 min of rinsing with

No rinsing

Water rinsing

1% calciumgluconate rinsing

Hexafluorine® rinsing

Discussion:

There is clear indication after results of penetration HF into the anterior chamber, that HF is early present within the anterior chamber. EDX gives (Fig 1) clear indication of penetration of Fluor ions. The neutralisation or amphoteric trapping of the Fluor ions can be demonstrated by means of the experiments of Fig. 2 that show clearly, that the Hexafluorine® solution is able to prevent precipitation of CaCl_2 with HF indicating the chemical inactivity of the Fluor ion. There is evidence of action of the different rinsing schemes being proposed by former authors. There is clear visible less corneal opacity and less corneal damage with Hexafluorine® solution. No precipitation within the corneal stroma occurs with Hexafluorine®. The evidence of the action of water and calciumgluconate rinsing are obvious, but corneal opacities are completely unacceptable in clinical result of visual rehabilitation.

- (1) Spoler F, Frenz M, Forst M, et al. Analysis of hydrofluoric acid penetration and decontamination of the eye by means of time-resolved optical coherence tomography. Burns. 2007 Sep 13
- (2) McCulley J. Ocular hydrofluoric acid burns. Animal model, mechanism of injury and therapy. Trans Am Ophthalmol Soc 1990;88:649-84.
- (3) Hall AH, Soderberg K, Kuusinen P, Mathieu L. An improved method for emergent decontamination of ocular and dermal hydrofluoric acid splashes. Vet Hum Toxicol 2004;46:216-8.
- (4) Hojer J, Personne M, Hulten P, Ludwigs U. Topical treatments for hydrofluoric acid burns: a blind controlled experimental study. J Toxicol Clin Toxicol 2002;40:861-6.