

## Use of an Amphoteric Solution in Eye, Skin and Oral Chemical Exposures: Retrospective Multicenter Clinical Case Series

Fortin JL<sup>1,2,3,4</sup>, Fontaine M<sup>4</sup>, Bodson L<sup>5</sup>, Depil-Duvala A<sup>6</sup>, Bitar MP<sup>1</sup>, Macher JM<sup>1,7</sup>, Paulin P<sup>3</sup>, Ravat F<sup>4</sup> and Hall AH<sup>8,9\*</sup>

<sup>1</sup>Emergency Department, Belfort Montbéliard Hospital, 14 Mulhouse Street, 90 000 Belfort, France

<sup>2</sup>Preventive Medicine, 82 Bergson Street, 42 000 Saint-Etienne, France

<sup>3</sup>Medical Department, Sdis 25, 10 Clairière Street, 25 042, Besançon Cedex, France

<sup>4</sup>Burn Intensive Care Unit, Saint Joseph Saint Luc Hospital, 20 Quai Claude Bernard, 69007 Lyon, France

<sup>5</sup>Emergency Department, University Hospital, Sart Tilman B, 4000 Liege, Belgium

<sup>6</sup>Emergency Department, St-Luc-St-Joseph Hospital, 20 Quai Claude Bernard, 69 007 Lyon, France

<sup>7</sup>Emergency Department, Nouvel Hôpital Street 26, 88100 Saint-Dié-des-Voges, France

<sup>8</sup>Toxicology Consulting and Medical Translating Services, P.O. Box 1255, Azle, Texas 76098, USA

<sup>9</sup>Colorado School of Public Health, University of Colorado-Denver, Denver, Colorado, USA

\*Corresponding author: Alan H Hall, Medical Toxicologist, Toxicology Consulting and Medical Translating Services, P.O. Box 1255, Azle, TX 76098-1255, USA, Tel: 1-307-399-1564; E-mail: OldEDDoc@gmail.com

Received date: February 22, 2017; Accepted date: March 21, 2017; Published date: March 27, 2017

Copyright: © 2017 Fortin JL, et al. This is an open-access article distributed under the terms of the Creative Commons Attribution License, which permits unrestricted use, distribution, and reproduction in any medium, provided the original author and source are credited.

### Abstract

**Introduction:** A polyvalent amphoteric flushing solution (Diphoterine®) has been in use for a number of years, mainly in industrial settings for decontamination of acid, base, and other corrosive or irritant substances eye and skin splashes.

**Methods:** Retrospective collection of 34 cases from several centers reporting use of Diphoterine® decontamination of eye, skin or oral chemical exposures. The following data were retrieved: exposure circumstances (workplace, domestic, deliberate assault), chemical nature and pH, exposure type, initial clinical signs, clinical signs after flushing, initial and final visual analog scale (VAS) pain ratings, consulting specialist physicians' conclusions.

**Results:** 58.8% of the 34 cases were occupational exposures, 29.4% were domestic, 5.9% occurred in schools, and 5.9% were deliberate chemical assaults. Of involved chemicals, 11 were basic substances, 11 were acidic, 1 was an oxidizing substance, 2 were solvents, and 9 were miscellaneous substances. There were 21 ocular exposures, 8 cutaneous exposures, 4 mixed (ocular/cutaneous), and 1 oral exposure. Initial clinical findings in ocular exposures were: pain, blepharospasm, hyperemia, palpebral edema, excessive tearing, and blurred vision. Of cutaneous exposures, 1 was a deep necrotic injury and 7 were superficial. Median (IQR) VAS before flushing with Diphoterine® was 7; VAS after ocular or skin flushing was 1.

**Conclusion:** Early application of the amphoteric solution to the eye or skin reduces the intensity of pain associated with chemical injury. While randomized clinical trials are lacking, early use of the amphoteric solution appears to reduce the incidence of sequelae.

**Keywords:** Diphoterine®; Amphoteric solution; Eye decontamination; Skin decontamination; Oral decontamination; Chemical burns; Chemical injuries

(SMUR) or in accident and emergency departments). In these circumstances, use of this solution may be more delayed than in industrial settings.

### Introduction

A polyvalent amphoteric flushing fluid (Diphoterine® solution) has been utilized for a number of years for decontamination of eye and skin chemical splashes, mainly in industrial settings. Application of this flushing fluid as soon as possible after the chemical splash at the accident site can prevent or limit the consequences.

Recently, a number of emergency departments have begun using this amphoteric flushing fluid in either the pre-hospital or hospital settings (use by the mobile emergency and intensive care services

### Methods

A retrospective multicenter case series of patients with chemical splash exposures decontaminated with Diphoterine® was assembled from the following hospital emergency departments and pre-hospital services for the years 2013 to 2016:

- Emergency Department, Belfort Hospital (France)
- Emergency Department, Montbéliard Hospital (France)
- Emergency Department, Evreux Hospital (France)

- Emergency Department, Lyon Saint-Joseph-Saint-Luc Hospital (France)
- Emergency Department, Liege Teaching Hospital (Belgium)
- Emergency Department, Saint-Dié Hospital (France)
- Medical Department, Departmental Fire and Rescue Service, Doubs (France)

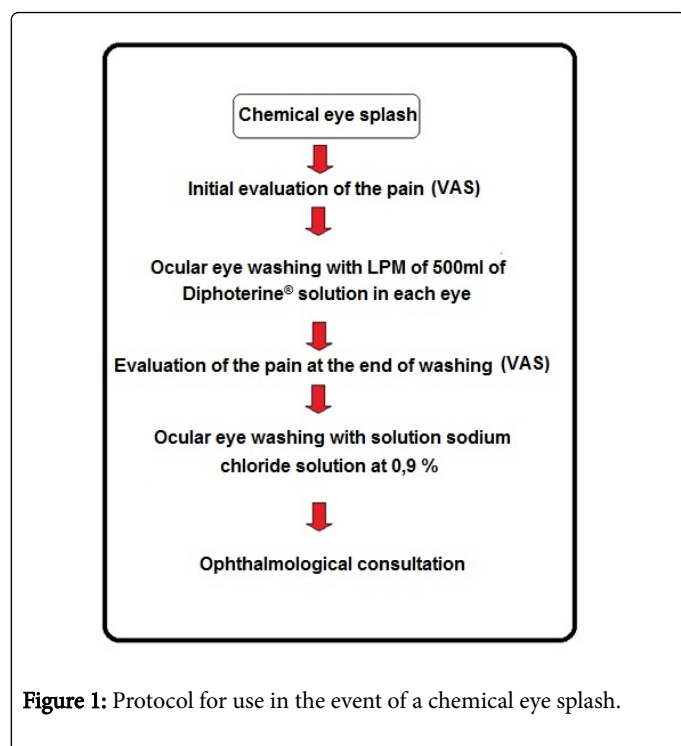
Thirty-four patients with chemical splash exposures presenting to the above emergency services were included. The following data were retrieved from each patient's medical records and recorded: age, gender, exposure circumstances, chemical nature and pH, type of exposure, initial clinical symptoms and signs, clinical symptoms and signs after Diphoterine® decontamination, pain assessment before, during, and after Diphoterine® flushing using a Visual Analog Scale (VAS; 0-10), time interval between exposure and beginning flushing, and consulting specialists' conclusions.

The Wilcoxon Rank Sum Test was utilized to compare the VAS pain level before and after Diphoterine® with  $p < 0.05$  considered statistically significant.

The amphoteric flushing solution (Diphoterine®) was used in compliance with the following protocols:

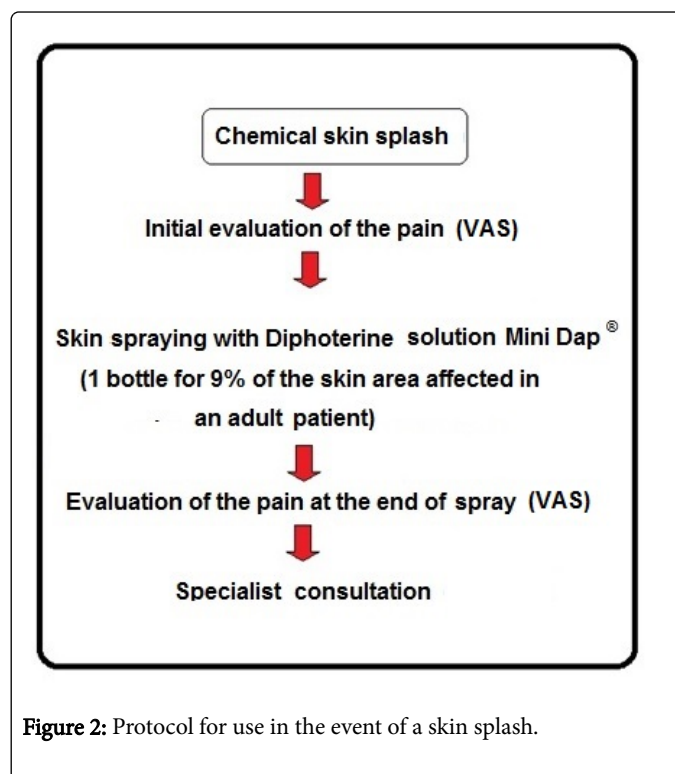
For Eye Splashes:

- Use of a 500 mL container of Diphoterine® solution;
- A rapid and initial VAS pain assessment was conducted before flushing of each involved eye with 500 mL of Diphoterine® solution;
- VAS pain intensity was assessed during and after flushing;
- Afterwards, rinsing with 500 mL of normal saline was done to prevent dry-eye syndrome because of the hypertonicity of Diphoterine® solution;
- Then, consultation with an ophthalmologist. (See Figure 1: Protocol for use in the event of eye splashes)



For Skin Splashes:

- Use of a 200 mL container of Diphoterine® solution;
- A 200 mL Diphoterine® container enables decontamination of
- ~9% of the Total Body Surface Area (TBSA) of an adult patient;
- A rapid initial assessment of the VAS pain level was done before flushing.
- At the conclusion of flushing, the VAS pain level was again assessed;
- Then, a burn specialist's opinion was obtained. (See Figure 2: Protocol for use in the event of skin splashes.)



## Results

Thirty-four patients were included in the retrospective study. Details of each case described by exposure circumstances (isolated eye lesions, isolated skin lesions, mixed eye and skin lesions, oral lesions) are shown in Tables 1a-1d. The median age of the patients was 37 years (IQR 25-45) and the male/female gender ratio was 61.30/38.70.

| Clinical cases | Eye lesion        | Chemical pH   | Interval between splash washing and | Initial clinical signs   | Initial VAS | Clinical signs post-washing  | Final VAS | Specialist opinion           |
|----------------|-------------------|---|-------------------------------------|--|-------------|--|-----------|------------------------------|
| No.1           | Bilateral lesions | Euphorbia lathyrus latex<br>pH=9  | 310 min                             | Blepharospasm<br>Eye pain<br>Palpebral edema                           | 10          | Decrease of pain and blepharospasm                                 | 3         | Moderate conjunctival lesion |
| No.2           | Bilateral lesions | Tear gas agent  | 30 min                              | Ocular hyperemia<br>Eye pain   | 10          | Resolution of hyperemia and pain                                   | 0         | No conjunctival lesion       |
| No.3           | Unilateral lesion | Acrylic coating   | 20 min                              | Ocular hyperemia<br>Eye pain   | 6           | Resolution of hyperemia<br>Disparition of pain                     | 0         | No conjunctival lesion       |
| No.9           | Bilateral lesions | CaOH <sub>2</sub>   | 89 min                              | Ocular hyperemia, pain, palpebral edema, no reduction in visual acuity | 10          | Decrease of pain   | 3         | No ophthalmological lesion   |
| No.10          | Unilateral lesion | Mewa Bio-Circle® degreasing agent –<br>pH=1,5                                   | 110 min                             | Blurred vision, left eye clouding                                      | 1           | Decrease of initial symptoms                                       | 0         | No ophthalmological lesion   |
| No.11          | Unilateral lesion | Indal Proclean® detergent for dairy equipment cleaning<br>pH=1,5                |                                     | Hyperemia, blurred vision<br>Eye pain                                  | 9           | Disparition of initial symptoms                                    | 3         | No ophthalmological lesion   |
| No.12          | Unilateral lesion | Bactifoam® alkaline liquid disinfectant<br>pH=13                                | 71 min                              | Ocular hyperemia<br>Blepharospasm<br>Eye pain                          | 6           | Resolution of the hyperemia and blepharospasm<br>Reduction of pain | 1         | No ophthalmological lesion   |
| No.13          | Bilateral lesions | 98% sulfuric acid<br>pH=1   | 1 min                               | Mild eye pain  | 3           | Resolution of pain   | 0         | No ophthalmological lesion   |
| No.15          | Unilateral lesion | Resosanit saphir®<br>pH=1   | 55 min                              | Eye pain   | 4           | Diminution of pain   | 2         | No ophthalmological lesion   |
| No.16          | Bilateral lesions | Caustic Soda  | 40 min                              | Ocular hyperemia<br>Mild eye pain                                      | 2           | Resolution of the hyperemia and pain                               | 0         | No ophthalmological lesion   |
| No.17          | Unilateral lesion | Solvent J900®   | 1 min                               | Ocular hyperemia<br>Eye pain   | 7           | Diminution of pain   | 2         |                              |
| No.18          | Bilateral lesions | Tear gas agent  |                                     | Eye pain<br>Watering   | 9           | Diminution of pain   | 5         |                              |
| No.22          | Bilateral lesions | Disinfectant P3-topactive®DES<br>Peracetic acid and hydrogen peroxide<br>pH=3,4 | 87 min                              | Hyperemia<br>Blurred vision<br>Eye pain                                | 5           | Disparition of hyperemia, blurred vision and eye pain              | 1         | No ophthalmological lesion   |

|       |                   |  |         |   |   |   |   |                              |
|-------|-------------------|--|---------|---|---|---|---|------------------------------|
| No.23 | Unilateral lesion | Degreaser disinfectant concentrate Atout Vert 302 ®<br>pH=2,5        | 180 min | Eye pain                                | 5 | Disparition of eye pain                                 | 0 | No ophthalmological lesion   |
| No.26 | Bilateral lesions | Acetone Biotech Biologique Onix®                                     | 140 min | Hyperemia<br>Blurred vision<br>Eye pain | 4 | Disparition of eye pain, blurred vision and eye pain    | 0 |                              |
| No.27 | Unilateral lesion | Ammonium hydroxide, Silver Nitrate, Oxalate ammonium chloride Barium | 85 min  | Hyperemia<br>Blurred vision<br>Eye pain | 2 | Disparition of eye pain, blurred vision and eye pain    | 0 | No ophthalmological lesion   |
| No.30 | Unilateral lesion | Methyl methacrylate OPTIPAC 60 ®                                     | 90 min  | Hyperemia<br>Blurred vision<br>Eye pain | 4 | Disparition of eye pain, blurred vision<br>And eye pain | 0 |                              |
| No.31 | Unilateral lesion | Phosphoric acid 20%  | 95 min  | Hyperemia<br>Eye pain                   | 8 | Disparition of eye pain and hyperemia                   | 0 |                              |
| No.32 | Unilateral lesion | Butylhydroxytoluene Stronghole®                                      | 131 min | Hyperemia<br>Blurred vision<br>Eye pain | 3 | Disparition of eye pain and hyperemia                   | 0 |                              |
| No.33 | Bilateral lesions | Chlorhexidine 0,2%   |         | Hyperemia<br>Eye pain                   | 7 | Disparition of hyperemia and pain                       | - |                              |
| No.34 | Unilateral lesion | Anios gel ®<br>pH=5,5  | 6 min   | Hyperemia<br>Eye pain                   | 6 | Disparition of hyperemia and pain                       | 1 | Moderate conjunctival lesion |

**Table 1a:** Presentation of the isolated eye lesions.

| Clinical cases | Chemical pH                                | Interval between splash and washing | Initial clinical signs  | Initial VAS | Clinical signs post-washing                                   | Final VAS | Specialist opinion Evolution            |
|----------------|--|-------------------------------------|---|-------------|---|-----------|---|
| No.4           | AGS 60 ®<br>Anti graffiti product<br>pH=14 | 90 min                              | Pain<br>Deep lesion   | 8           | Pain resolution<br>Persistence of deep lesion                 | 0         | Deep lesions<br>Excision and skin graft |
| No.8           | 98% sulfuric acid<br>pH=1                  | 1 min                               | Erythematous plaques on the neck and chest                          | 9           | Persistence of the plaques<br>Subsequent spontaneous recovery | 3         | Superficial burns                       |
| No.14          | 4% formaldehyde                            | 38 min                              | Erythema on the neck, right arm and anterior surface of both thighs | 5           | Resolution of erythematous plaques                            | 0         | No lesion or pain at hour 48            |
| No.19          | 2% Caustic soda                            |                                     | Erythema<br>TBSA=10%  | 5           | Reduction of pain   | 1         | Superficial burns                       |
| No.20          | BIOXAL ®                                   | 50 min                              | Erythema  | 1           | Disparition of erythema                                       | 0         | No lesion or pain at hour 48            |

|       |  |         |                    |   |                   |   |  |
|-------|--|---------|--------------------|---|-------------------|---|--|
|       | Acetic acid, Peracetic acid and hydrogen peroxide pH=1,6 |         |                    |   |                   |   |  |
| No.24 | Cement pH=13   | 360 min | Skin pain          | 8 | Reduction of pain | 2 |  |
| No.25 | Cement pH=13   | 360 min | Skin pain          | 7 | Reduction of pain | 0 |  |
| No.29 | Caustic Soda   | 45 min  | Phlyctenae TBSA=1% |   | Reduction of pain | 4 |  |

**Table 1b:** Presentation of the isolated skin lesions.

| Clinical cases | Chemical pH                | Interval splash washing between and | Initial clinical signs                         | Initial VAS | Clinical signs post-washing                     | Final VAS | Specialist opinion Evolution  |
|----------------|----------------------------|-------------------------------------|--|-------------|---|-----------|---|
| No.5           | Aluminum-manganese mixture | 20 min                              | Eye pain<br>Blepharospasm<br>Facial phlyctenae | 10          | Conjunctival irritation of the right eye        | 4         | Conjunctival ulcer of the right eye<br>Resolution of the blepharospasm<br>Superficial burns |
| No.6           | 98% sulfuric acid pH=1     | 5 min                               | Eye pain<br>Facial erythema                    | 9           | Resolution of the pain and facial erythema      | 2         | No ophthalmological lesion<br>Superficial burns   |
| No.7           | 25% sodium hydroxide pH=12 | 308 min                             | Facial erythema<br>Eye pain                    | 8           | Resolution of hyperemia and the facial erythema | 2         | No ophthalmological lesion<br>Superficial burns   |
| No.28          | Glyphosate de soude        | 65 min                              | Blepharospasm<br>Facial phlyctenae             | 9           | Resolution of blepharospasm                     | 6         | No ophthalmological lesion<br>Superficial burns   |

**Table 1c:** Presentation of the mixed lesions (skin and eyes).

| Clinical cases | Chemical pH | Interval between splash washing and | Initial clinical signs   | Initial VAS | Clinical signs post-washing                | Final VAS | Specialist opinion Evolution            |
|----------------|-------------|-------------------------------------|--------------------------|-------------|--|-----------|---|
| No.21          | Ammoniac    | 555 min                             | Buccal and lingual burns | 3           | Decrease lingual burn<br>Reduction of pain | 1         | No taste loss<br>No burn after 48 hours |

**Table 1d:** Presentation of the Oral lesions.

In 58.8% of cases, the chemical exposure occurred in an industrial setting. In 29.4%, exposure was in a domestic setting, and in 5.9% of cases exposure occurred in an educational setting. In 5.9% of cases, the chemical exposure was due to deliberate assault.

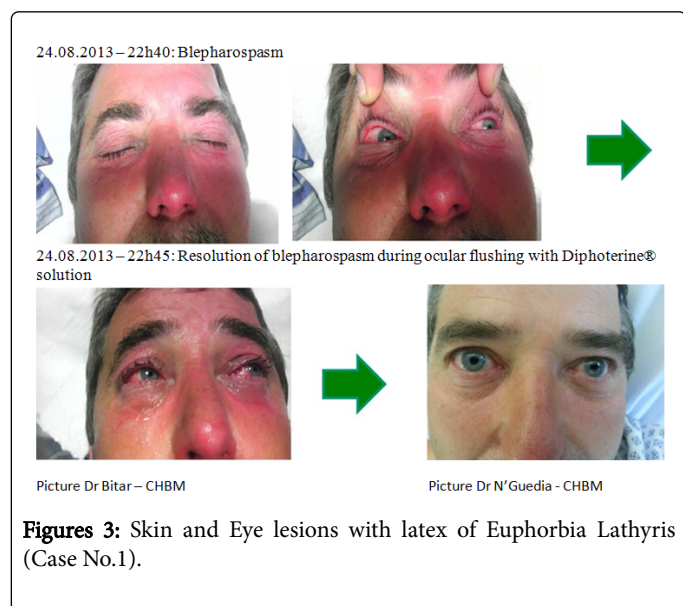There were 21 isolated ocular injuries (9 bilateral; 12 unilateral), 8 isolated skin injuries, 4 mixed eye and skin injuries, and 1 oral exposure. Involved chemicals were basic substances (11 cases), acidic substances (11 cases), an oxidizer (1 case), solvents (2 cases), and

miscellaneous chemical substances (9 cases; acrylic coating, lacrimating agent, etc.).

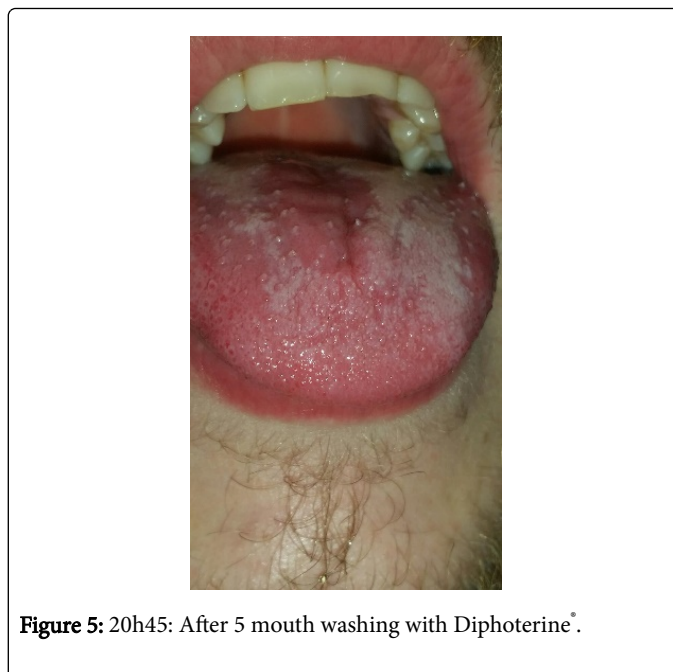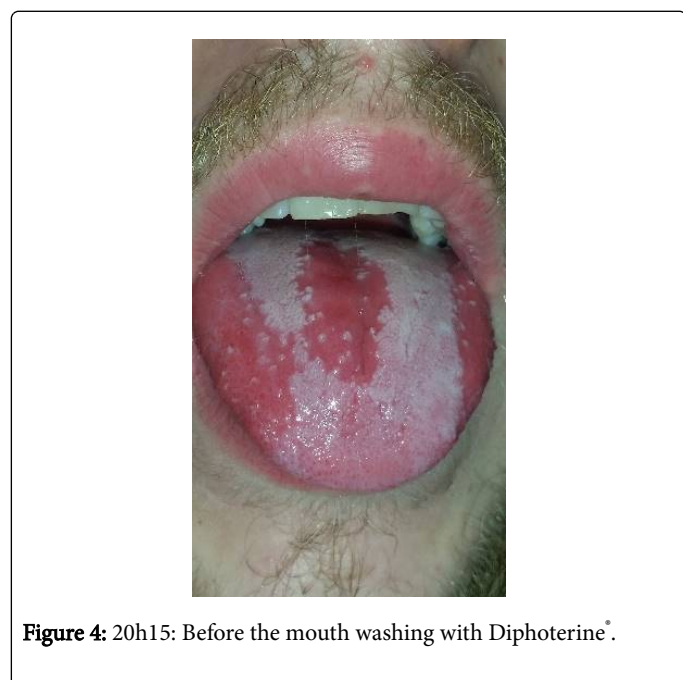
Among the 25 isolated or mixed ocular injuries, the following signs and symptoms were noted: eye pain (18 cases), blepharospasm (4 cases; see Figure 3 for an example secondary to latex of *Euphorbia lathyris* exposure), conjunctival hyperemia (15 cases), palpebral edema (2 cases), excessive tearing (1 case), and blurred vision (7 cases). Among the 8 isolated skin injuries, there was 1 case with a deep



necrotic lesion and 7 cases of superficial lesions, erythema, or phlyctenae.



Only 1 case of an oral burn due to accidental ingestion of ammonia stored in an unlabeled bottle was noted. The patient immediately expectorated the ammonia. The Tongue lesion before and after Diphoterine® rinsing repeated 5 times as a mouthwash and expectorated is shown in Figures 4 and 5.



#### Initial and final pain level assessment by VAS

The initial pain intensity ranged from 3 to 10 on the VAS. The initial median VAS score before Diphoterine® eye or skin flushing was 7 (IQR: 4-9). The final median VAS pain intensity score was 1 (IQR: 0-3). Thus, the difference between before-flushing and after-flushing with Diphoterine® was significant (Wilcoxon Rank Sum Test;  $p < 0.0001$ ).

The time interval between exposure and Diphoterine® solution eye and/or skin flushing ranged from 1-555 minutes (median: 77.5 minutes; IQR: 30-131 minutes).

#### Clinical signs and symptoms after diphoterine® eye and/or skin flushing

**Ocular signs and symptoms:** Resolution of eye pain in 14 cases (final VAS 0 or 1); marked decrease of eye pain in 7 cases (final VAS 2 or 3); persistence of moderate eye pain after Diphoterine® eye flushing in 3 cases related to chemical lesions induced by a reducing agent (aluminum-magnesium mixture; Case No. 6), "tear gas" (Case No. 18) and glyphosate soda (Case No. 28); Resolution of blepharospasm in the 4 observed cases (Cases Nos. 1, 5, 12, 28); Reduction of initial blurred vision in the 7 observed cases with regression or resolution of initial blurred vision (Cases Nos. 10, 11, 22, 26, 27, 30, 32); Resolution of initial palpebral edema in the 2 observed cases (Cases Nos. 1 and 9)

**Cutaneous signs and symptoms:** Resolution of all initial skin lesions in the 7 observed cases with superficial lesions (erythema or phlyctenae) by 48 hours post-exposure; In the 1 case of deep necrotic skin injury (Case No.4), there was no local improvement following Diphoterine® flushing. Recovery followed surgical excision and skin grafting. Of note, Diphoterine® flushing was quite delayed after exposure.

**Oral signs and symptoms:** In the only case of mouth exposure (to ammonia; Case No. 21), after 5 repeated Diphoterine® mouthwashes followed by expectoration (no swallowing), a reduction of the chemical

injury was noted (Figures 4 and 5). On the following day, the patient was pain free and had no loss of taste sensation.

**Results of ophthalmology specialist consultations:** No lesions were noted in 12 patients; Six patients had minimal eye findings (moderate conjunctival lesions which resolved in a few days with standard eye drop treatment); One patient (Case No. 5) had a superficial ulceration of the cornea.

## Discussion

It is generally accepted that decontamination of eye or skin chemical splashes should be done as soon as possible after exposure. While potable water as the flushing fluid has been utilized for a very long time, it is perhaps currently not the best option [1]. Diphoterine® is a polyvalent amphoteric solution for flushing splashed chemicals off the skin or surface of the eyes. It has been used efficaciously for a number of years in industrial settings [2-5]. In the European Union, Diphoterine® solution is a Class II medical device. It is not irritating to the eyes or skin, is not sensitizing in guinea pigs or humans, is non-toxic (rat oral/dermal LD50 >2,000 mg/kg) and is not mutagenic in the Ames test [1,6].

### Diphoterine® solution has multiple methods of action

- As an aqueous solution, it flushes a large portion of the splashed chemical substance from the surface of the skin or eyes through mechanical entrainment and dilution;
- As an hypertonic solution, it limits penetration of the splashed chemical substance into the deep tissue layers of the skin or eyes by creating an osmotic pressure gradient;
- As an amphoteric solution (able to bind opposing chemical groups such as acids/bases or oxidizing/reducing agents), it halts the aggressive action of corrosive or irritant chemical substances.

Comparative studies have demonstrated the efficacy of Diphoterine® solution. Gerard et al. [7] compared the action of Diphoterine® solution and normal saline *in vivo* in the context of ammonium hydroxide eye injuries. These authors found a lack of stromal edema when Diphoterine® solution was used and its presence when flushing was with normal saline. This finding is supported by the difference of osmotic pressure between the two flushing fluids (respectively ~800 mosmols/kg for Diphoterine® solution versus 280 mosmols/kg for normal saline, while the osmotic pressure of the cornea is 420 mosmols/kg). As a biochemical rationale, the pH curve was decreased during flushing with Diphoterine® solution.

In a 2002 review, Hall et al. [1] showed that Diphoterine® solution was more efficacious than water in various industrial studies. Nehles et al. [4] found that when workplace corrosive substances eye and skin splashes were flushed with Diphoterine®, there was no need for medical treatment other than decontamination, and there were no sequelae and no lost work time.

Cavallini and Casati [8] and Cavallini et al. [9] investigated wound healing and concentrations of  $\beta$ -endorphin, Substance P, and interleukin IL-6 in a rat *in vivo* study of concentrated hydrochloric acid skin injury flushed with either Diphoterine® solution, normal saline, or calcium gluconate solution. In the Diphoterine® group versus the normal saline and calcium gluconate solution groups, the following were observed:

- A more important decrease in lesion size in the Diphoterine® solution group;
- Significant beneficial changes in biological markers of pain in the Diphoterine® solution group: a significant decrease in Substance P concentration at 48 h ( $p < 0.05$ ) and a significant increase in  $\beta$ -endorphin at 7 days ( $p < 0.05$ );
- A significant decrease in inflammation as shown by decreased IL-6 concentrations at 48 h ( $p < 0.05$ ) and enhanced tissue repair.

Merle et al. [10,11] conducted a clinical study of 66 patients with deliberate assault eye splashes with a base chemical substance (ammonium hydroxide; Alkali®) in Martinique. These authors reported that, compared to normal saline flushing, Diphoterine® solution was more efficacious for decreasing the time to corneal re-epithelization in patients with Roper-Hall scale Grade I and II lesions and seemed to be more suitable for emergent flushing of corrosive chemical substance exposed eyes. Schrage et al. [12] considered the pathophysiology of chemical ocular lesions and compared various eyewash solutions. Diphoterine® appeared to be the best option.

Ioannidis et al. [13] reported the case of a 76-year-old man with eye injury due to exposure to the latex of the *Euphorbia lathyris* plant. Despite flushing with 8 liters of normal saline followed by treatment with dexamethasone and cicatrizing eye drops, the patient developed a corneal ulcer and severe pain which necessitated a 3-day hospitalization.

This clinical course is in sharp contrast to Case No.1 reported here; a 59-year-old man who developed facial skin injuries, eye injuries, and severe pain 4 hours after handling the latex of this same plant. *Euphorbia lathyris* is a plant used by gardeners; in particular the cut stalks are inserted into mole burrows. The latex from the cut stalks has alkylating and base properties (pH=9) and also contains protease enzymes which repel moles.

After exposure at home, the patient took 10 mg of morphine (already in his possession for the treatment of fibromyalgia) and performed an eye wash with Dacroserum® solution which did not alleviate the pain. During the initial examination in the hospital emergency department, the patient had blepharospasm, facial lesions, and ocular pain which was scored as 8/10 on the VAS, as well as persistence of blepharospasm. Eye flushing with normal saline resulted in an increase in ocular pain (10/10 on the VAS). Flushing with Diphoterine® solution (250 mL for each eye) resulted in a decrease of ocular pain (6/10 on the VAS) and resolution of blepharospasm after 15 minutes (Figure 3). After 55 minutes, ocular pain had completely resolved. Ophthalmological examination a few hours later showed only a mild conjunctival lesion. As compared to the case reported by Ioannidis et al. [13], flushing with Diphoterine® solution resulted in a less severe lesion and rapid pain relief.

Donoghue [5] compared the efficacy of Diphoterine® solution with that of water for decontamination of alkaline chemical splashes in a clinical study involving 180 workers. In the group treated with Diphoterine® solution, there were no signs of lesions in 52.9% of cases versus 21.4% of cases flushed with water. Moreover, grade III and IV lesions were significantly less numerous in the Diphoterine® solution first group (7.9 vs. 23.8%;  $p < 0.001$ ).

Zack-Williams et al. [14] published a 2-year comparative evaluation study. There was a significant change in the wound pH pre- and post-flushing with Diphoterine® solution compared to water flushing (pH change of 1.076 versus 0.4;  $p < 0.05$ ). There were no significant differences in time to healing, length of hospital stay or need for

surgery. Based on the retrospective case series presented here, Diphoterine® solution could be valuable for flushing of corrosive and irritant chemical splashes in the hospital and pre-hospital settings.

Bvrar [15] published a comparative study of CS “tear gas” exposures in Slovenian police officers flushed with Diphoterine® solution versus no flushing. The policemen refused to compare Diphoterine® solution with water flushing because of increased pain when CS exposures were flushed with water. Six policemen were exposed to CS only. A second group of 8 policemen sprayed their faces with Diphoterine® solution before CS exposure and a third group of 8 policemen sprayed their faces with Diphoterine® solution after exposure. The time between exiting the CS cloud and arriving at the “ready for action” checkpoint was measured. Facial pain both inside the CS cloud and at the checkpoint was assessed using a 0-10 visual analog scale (VAS).

The pain level inside the CS cloud was significantly lower in the group that pre-treated with Diphoterine® solution ( $5.6 \pm 1.1$ ;  $p=0.1$ ) versus the CS only group ( $9.7 \pm 0.5$ ). In the post-CS-exposure treatment group, it was similar ( $9.1 \pm 0.4$ ). The time interval between CS exposure and arrival at the checkpoint was significantly shorter in the Diphoterine® solution pre-treatment group ( $1.26 \pm 0.44$  minutes) than in the CS only group ( $2.28 \pm 0.25$  minutes;  $p=0.04$ ) and in the post-exposure treatment group ( $2.30 \pm 0.48$  minutes;  $p=0.02$ ) where it was not different. The residual pain at the checkpoint in the Diphoterine® pre-CS-exposure ( $1.1 \pm 0.4$ ) and post-exposure ( $1.4 \pm 0.7$ ) groups was similar, with significantly less pain than in the CS only group ( $2.3 \pm 0.5$ ;  $p=0.02$ ). In this study, post-CS-exposure decontamination with Diphoterine® solution reduced facial pain whereas pre-CS-exposure treatment reduced both pain and recovery time [15]. These findings are in substantial agreement with those reported in French gendarmes by Viala et al. [16].

Lynn et al. [17] published an independent systematic review of the safety and efficacy of Diphoterine® solution compared to water and normal saline for the decontamination of ocular and cutaneous chemical burns in humans. All studies published in peer-reviewed journals up to May 2016 were eligible for consideration. Such published data must have included Diphoterine® solution for decontamination of eye and/or skin chemical splashes as well as meeting other specified criteria. Acceptable studies had to use either a quantitative (e.g., number of lost workdays) or qualitative (e.g., level of erythema) approach when determining cutaneous and/or ocular lesion outcomes. These authors concluded that, despite a relatively small number of published studies, Diphoterine® solution is safe and highly efficacious in improving healing times, healing sequelae, and pain management of chemical skin and eye injuries in humans. Outcomes are significantly improved as compared to water or normal saline decontamination. These authors concluded:

*“We recommend this product be readily available to emergency responders and companies that expose their employees to hazardous chemical substances in order to improve healing sequelae, pain management, and lost work days from these types of burns”* [17].

Overall, Diphoterine® solution limits the action of the splashed chemical substance on the tissues. Through its physical actions, it removes the chemical substance in contact with the tissues (mechanical and osmotic actions). In addition, flushing with Diphoterine® solution enables the tissues to return to a physiologically acceptable pH. Lesion formation is thus halted. Since the tissue is no longer under aggression and in a physiologically acceptable environment, pain and inflammation decrease. The published studies

reviewed show the same mechanisms, during and after flushing with Diphoterine® solution, as evidenced by decrease in pain and reduction of sequelae.

The majority of the cases reported here showed symptomatic improvement following Diphoterine® solution flushing. Absorption of the splashed chemical substance into the tissues and resultant cell damage are halted by effective flushing with Diphoterine® solution.

## Conclusion

Eye and skin chemical lesions account for ~4% of all burn cases attending emergency departments. The context is often a domestic accident rather than an occupational exposure. The small number of chemical lesions resulting from occupational accidents observed in the hospital might be explained by the use of the polyvalent, amphoteric Diphoterine® solution as an emergency decontamination measure in workplace settings. Rapid use of Diphoterine® solution enables a reduction in the duration of tissue chemical exposure and hence a reduction in the lesions induced.

Both *in vitro* and *in vivo*, Diphoterine® solution has been shown to be effective on eye, skin and mucous membrane chemical injuries. For the best results, Diphoterine® solution flushing should begin as soon as possible after the chemical splash occurs in order to prevent or lessen lesion development. As more data are accumulated, the efficacy of Diphoterine® solution should become more apparent to pre-hospital responder organizations and emergency departments.

## Conflict Delineations

AHH is a paid consultant to Laboratoire Prevor, Valmondois, France, manufacturer of Diphoterine®. All other authors report no conflicts of interest.

## References

1. Hall AH, Maibach HI (2006) Water decontamination of chemical skin/eye splashes: a critical review. *Cutan Ocul Toxicol* 25: 67-83.
2. Hall AH, Blomet J, Mathieu L (2002) Diphoterine for emergent eye/skin chemical splash decontamination: a review. *Vet Hum Toxicol* 44: 228-231.
3. Minaro L, Bedry R, Verdun-Esquer C, Brochard P, Favarrri-Garrigues JC (2000) Brûlures chimiques: place de la Diphoterine®. *Archives des Malades Professionnelles et de Medecine du Travail* 61: 63-64.
4. Nehles J, Hall AH, Blomet J, Mathieu L (2006) Diphoterine for emergent decontamination of skin/eye chemical splashes: 24 cases. *Cutan Ocul Toxicol* 25: 249-258.
5. Donoghue AM (2010) Diphoterine for alkali chemical splashes to the skin at alumina refineries. *Int J Dermatol* 49: 894-900.
6. Hall AH, Cavallini M, Mathieu L, Maibach HI (2009) Safety of dermal Diphoterine application: An active decontamination solution for chemical splash injuries. *Cutan Ocul Toxicol* 28: 149-156.
7. Gérard M, Josset P, Louis V, Menarath JM, Blomet J, et al (2000) Existe-t-il un délai pour le lavage oculaire externe dans le traitement d'une brûlure oculaire par l'ammoniaque. Comparaison de deux solutions de lavage: serum physiologique et Diphoterine® [French]. *J Fr Ophtamol* 23: 449-458.
8. Cavallini M, Casati A (2004) A prospective, randomized, blind comparison between saline, calcium gluconate and Diphoterine for washing skin acid injuries in rats: effects on substance P and  $\beta$ -endorphin release. *Eur J Anaesthesiol* 21: 389-392.
9. Cavallini M, de Broccard F, Corsi MM, Fassati LR, Baruffaldi Preis FW (2004) Serum pro-inflammatory cytokines and chemical acid burns in rats. *Ann Burn Fire Dis* 27: 1-5.



- 
10. Merle H, Donnio A, Ayeboua L, Thomas F, Ketterle J, et al. (2005) Alkali ocular burns in Martinique (French West Indies). Evaluation of the use of an amphoteric solution as the rinsing product. *Burns* 31: 205-211.
  11. Merle H, Gérard M, Schrage N (2008) Ocular burns. *J Fr Ophthalmol* 31: 723-734.
  12. Schrage NF, Struck HG, Gerard M (2011) Recommendations for acute treatment for chemical and thermal burns of eyes and lids. *Ophthalmologie* 108: 916-920.
  13. Ioannidis AS, Papageorgiou KI, Andreou PS (2009) Exposure to *Euphorbia lathyris* latex resulting in alkaline chemical injury: a case report. *J Med Case Rep* 3: 115.
  14. Zack-Williams SD, Ahmad Z, Moiemens NS (2015) The clinical efficacy of Diphoterine® in the management of cutaneous chemical burns: a 2-year evaluation study. *Ann Burns Fire Disasters* 28: 9-12.
  15. Bvrar M (2016) Chlorobenzylidene malonitrile tear gas exposure: Rinsing with amphoteric, hypertonic, and chelating solution. *Hum Exp Toxicol* 35: 213-218.
  16. Viala B, Blomet J, Mathieu L, Hall AH (2005) Prevention of CS "Tear Gas" eye and skin effects and active decontamination with Diphoterine: Preliminary studies in 5 French Gendarmes. *J Emerg Med* 29: 5-8.
  17. Lynn DD, Zukin LM, Dellavalle R (2017) The safety and efficacy of Diphoterine for ocular and cutaneous burns in humans. *Cutan Ocul Toxicol*.