


available at [www.sciencedirect.com](http://www.sciencedirect.com)journal homepage: [www.elsevier.com/locate/burns](http://www.elsevier.com/locate/burns)

# Analysis of hydrofluoric acid penetration and decontamination of the eye by means of time-resolved optical coherence tomography

Felix Spöler<sup>a,\*</sup>, Markus Frentz<sup>b,c</sup>, Michael Först<sup>a</sup>, Heinrich Kurz<sup>a</sup>, Norbert F. Schrage<sup>b,c,d</sup>

<sup>a</sup> Institute of Semiconductor Electronics, RWTH Aachen University, Sommerfeldstraße 24, 52074 Aachen, Germany

<sup>b</sup> Aachen Centre of Technology Transfer in Ophthalmology, Karlsburgweg 9, 52070 Aachen, Germany

<sup>c</sup> Department of Ophthalmology, Aachen University, Pauwelsstraße 30, 52057 Aachen, Germany

<sup>d</sup> Department of Ophthalmology Cologne Merheim, Ostmerheimer Str. 200, 51109 Cologne, Germany

## ARTICLE INFO

### Article history:

Accepted 21 May 2007

### Keywords:

Eye irritation

Eye burn

Hydrofluoric acid burn

Optical coherence tomography

Hexafluorine

## ABSTRACT

So far the study of chemical burns has lacked techniques to define penetration kinetics and the effects of decontamination within biological structures. In this study, we aim to demonstrate that high-resolution optical coherence tomography (HR-OCT) can close this gap. Rabbit corneas were exposed *ex vivo* to 2.5% hydrofluoric acid (HF) solution, and microstructural changes were monitored in the time domain by OCT imaging. HF application and penetration resulted in shrinkage of the corneal thickness, interpreted as a result of osmolar changes and of loss of water-binding capacity, and a substantial increase in OCT signal amplitudes. The effectiveness of different rinsing solutions on the chemical burn was also evaluated. With tap water and with 1% calcium gluconate, the deep corneal stroma remained clear until the end of the rinsing period but became opaque afterwards. With Hexafluorine<sup>®</sup>, the cornea remained clear for 60 min after rinsing ceased. We conclude that HR-OCT can assist in the clinical evaluation of an *ex vivo* eye irritation test, and that decontamination of an HF burn using Hexafluorine<sup>®</sup> is efficient.

© 2007 Elsevier Ltd and ISBI. All rights reserved.

## 1. Introduction

Severe eye burns with hydrofluoric acid (HF) are rare but extremely hazardous [1]. Whereas most acidic substances tend to remain confined by coagulation necrosis to the corneal epithelium, HF readily penetrates the cornea. The high penetration power of HF is ascribed to the undissociated molecule, and the major toxic effect of HF to the dissociated fluoride anion. Formation of calcium fluoride within any affected tissue results in immediate cell death, in addition to the acidic effects of the compound. Evaluation of secondary prevention after chemical eye burn lacks an accomplished comparative approach using

standardised burn concepts under highly reproducible circumstances.

With the acute *ex vivo* eye irritation test (EVEIT), we have introduced a simple exposure model that is suitable for short-term experiments directly on enucleated globes as well as for long-term experiments and repeated exposures within a special culture system [2]. To expand the information accessible by this *ex vivo* test, we successfully applied optical coherence tomography (OCT) to monitor eye irritations, with high temporal and spatial resolution. This non-invasive, non-contact medical imaging method has gained wide acceptance in ophthalmology and in other medical disciplines on account of its high-resolution (HR) imaging capability [3].

\* Corresponding author. Tel.: +49 241 80 27896; fax: +49 241 80 22246.

E-mail address: [spoeler@iht.rwth-aachen.de](mailto:spoeler@iht.rwth-aachen.de) (F. Spöler).

0305-4179/\$34.00 © 2007 Elsevier Ltd and ISBI. All rights reserved.

doi:10.1016/j.burns.2007.05.004

OCT imaging of the anterior chamber of the eye was first demonstrated in 1994, allowing non-invasive assessment of the corneal thickness and visualisation of the corneal epithelium [4]. The suitability of ultrahigh-resolution OCT to image corneal structures, such as Bowman's and Descemet's membrane as well as the typical stromal structure, was demonstrated in an animal model [5,6] and in human cornea postmortem [7]. The ability of OCT to gather non-destructively a time series of a single sample, with time constants ranging from part of a second to long-term observation over several days, was used to address various matters under investigation. For example, wound healing after laser thermal injury was examined in skin equivalents using OCT and multiphoton microscopy [8]. In ophthalmology, dynamic OCT imaging was applied to study the corneal response to dehydration stress *in vivo* in a rabbit model [9], to quantify light backscattering within the cornea during corneal swelling [10] and to monitor glucose diffusion within the sclera [11]. The generation of cross-sectional images of tissue morphology at high speed with micrometer scale resolution is particularly useful in pharmacological and toxicological studies, which require ongoing monitoring of morphological changes [12].

In this article, we evaluate the potential of time-resolved high-resolution OCT imaging to monitor the dynamics of HF penetration during chemical eye burns, and to demonstrate the effectiveness of acute intervention procedures in the short-term EVEIT test. The regions of damaged corneal tissue are characterised in OCT with high contrast due to a significant increase in light scattering induced by structural changes within the cornea. In this study, we introduce a well-defined, diffusion-controlled and reliable model of exposure and decontamination. To demonstrate the capability of this new combination of OCT and EVEIT, we analysed the effect of rinsing solutions currently used in HF decontamination.

## 2. Materials and methods

### 2.1. *Ex vivo* eye irritation test

In the EVEIT, excised rabbit eyes replace the eyes of living animals involved, for example, in the Draize test. The short-term EVEIT selected for this study is performed on whole globes, to investigate acute damage and penetration depth during chemical eye burn. For long-term studies within the EVEIT system, including morphological healing or non-healing after a specific injury, excised rabbit corneas which are maintained under artificial conditions can be used; their behaviour during chemical burn is very similar to that of *in vivo* eye tissue [2].

In this investigation, enucleated white rabbit eyes were used. Rabbit heads were obtained from an abattoir and kept cool until enucleation of the eyes. The globes were then stored at 4 °C in a humid atmosphere to ensure preservation of the corneal epithelium. Only clear corneas without any epithelial defects were processed. All measurements were performed within 12 h of the animal's death. All eyes were kept at room temperature for 30 min before measurement.

A standardised amount of HF, 25 µl of 2.5% (1.25 mol/l) solution, was used to initiate chemical burn. A filter paper (MN

615 1/4; Machery-Nagel, Düren, Germany), 10 mm in diameter, was soaked with this solution and placed on the centre of the cornea at time point zero. By this means, a continuous film of the corrosive was attached to the surface of the cornea. After 20 s the filter paper was removed from the cornea.


Untreated burned eyes and burned eyes after rinsing were examined by means of OCT imaging. For rinsing we used tap water (Aachen, Germany, water hardness 1), calcium gluconate solution 1%, and Hexafluorine® (Prevor, Valmondis, France), following the instructions of Germany's Berufsgenossenschaft (employers' liability insurance association). Rinsing was started at a fixed time point (25 s after burning) and lasted for 15 min at a stable flow of 66.7 ml/min, using 1000 ml of solution in total. To achieve this, an intravenous infusion system (Braun-Melsungen, Melsungen, Germany) connected to a precision pump was used and placed, open-ended, directly over the centre of the cornea. This protocol differs from the recommendations of Prevor, who propose a rinsing period of 3 min for Hexafluorine® at a flow of 166 ml/min. Top-view photographic images of the burnt globes were recorded 15 min after application of HF (corresponding to the end of the rinsing period for the rinsed eyes) to document the visual outcome of the chemical injury with and without rinsing. For comparison, the effect of the rinsing solutions on the transparency and thickness of the cornea was also examined without preliminary HF application. The osmolarity of the tap water was 0.30 osmol/kg [13], and the osmolarities of the calcium gluconate solution and of Hexafluorine® were 0.048 and 1.229 osmol/kg, respectively.

Each experiment within this study was repeated three times, using enucleated eyes of different rabbits. Besides variations in the central corneal thickness of the untreated eyes, in the range of  $452 \pm 47$  µm, and subsequent deviations in the observed corneal thicknesses during treatment, no significant variations in experimental outcome of identical treatment conditions were observed.

### 2.2. Optical coherence tomography

The basic principles of OCT are extensively discussed elsewhere [14]. Briefly, OCT is the optical analogue to conventional medical sonography. For cross-sectional image reconstruction in OCT, near-infrared light backscattered from structures within the sample is analysed by low-coherence interferometry, and a light wave is split into a reference beam with variable path length, and a probe beam which is focused on the sample. An interference signal is only generated if the path difference between both arms is smaller than the coherence length of the light source. Therefore, the axial resolution in OCT is determined by the coherence length, and consequently by the spectral band width of the light source. As in microscopy, the lateral resolution in OCT is determined by the laser beam spot size on the sample.

For the HR-OCT system in this study, a Ti:sapphire laser oscillator (GigaJet 20, GigaOptics GmbH, Konstanz, Germany) centred at 800 nm was used as a low-coherence light source. Additional dispersion management within the laser cavity was deployed to optimise its coherence length to 3.6 µm in air. This light source was coupled into the fibre-based interferometer of a commercially available OCT system (Sirius 713,



**Fig. 1 – High-resolution OCT image of untreated rabbit cornea *ex vivo* (900  $\mu\text{m}$   $\times$  633  $\mu\text{m}$ ). A logarithmic false-colour scale is used.**

Heidelberg Engineering GmbH, Lübeck, Germany) [15]. The latter was modified to support the superior axial resolution specified by the coherence length of the Ti:sapphire oscillator.

The A-scan rate of the OCT system was 50 Hz and the number of data points for each A-line data acquisition was 512. The axial and lateral resolutions within tissue were 3 and 10  $\mu\text{m}$ , respectively. OCT images were composed of 560 A-scans with a lateral step size of 7  $\mu\text{m}$  for static tissue examination. Images with a width of 700  $\mu\text{m}$  (100 A-scans per image) were taken at a rate of 30 frames per minute. A refractive index of 1.385 was used for the conversion of optical to geometrical path lengths measured by OCT [16]. It was assumed that the index of refraction does not change significantly during chemical burn. The same colour scale was used for all OCT images.

All OCT measurements were performed at the centre of the cornea, which was positioned horizontally. For comparison, the cornea of each eye was imaged directly before application of HF. Chemical injury was induced as described above. The development of eye burns and the effectiveness of decontamination were directly monitored by OCT imaging. To follow the penetration of HF within the cornea, OCT imaging was started directly after removal of the HF-soaked filter paper. To

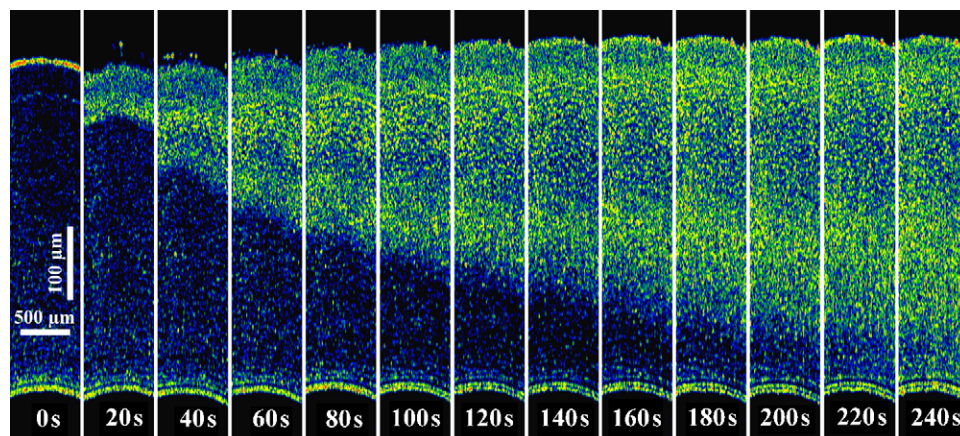
visualise the effectiveness of rinsing, tomograms of rinsed and unrinsed eyes were recorded at time points of 15, 30, 45, 60 and 75 min after application of HF.

### 3. Results

Fig. 1 shows a characteristic tomogram of an untreated rabbit cornea *ex vivo*, imaged by our HR-OCT system. The epithelium, stroma, Descemet's membrane endothelial layer and, allusively, the stromal fibres can be distinguished. The Descemet's membrane separating the stroma from the endothelium is imaged as a low-scattering band within the higher-scattering surrounding layers.

The scattering cross-section and therefore the OCT signal amplitude of tissue are determined by the microstructure. As the interaction of HF with corneal tissue involves structural changes, these modifications of corneal morphology were observed by OCT imaging. This is demonstrated in Fig. 2, where a time-series data set of a rabbit cornea *ex vivo* is shown undergoing superficial exposure to 25  $\mu\text{l}$  HF (2.5%). The corresponding cross-sectional image of the cornea before HF application is displayed in the leftmost part of the figure. Time steps within the subsequent images refer to zero time delay, when the acid is applied to the cornea. The tissue damage induced by the corrosive is delineated with high contrast, indicated by a significant increase in OCT signal intensity compared with the image before the application of HF. Full penetration of the cornea is completed within 240 s. To evaluate the dependency of the penetration time on the HF concentration, another image sequence was recorded after application of a 10% solution of HF (not shown), when full corneal penetration was observed within 100 s.

To study the effectiveness of rinsing as secondary prevention procedure, tomograms of HF-burned eyes, without rinsing and after rinsing with different solutions, were recorded at different time points after topical application of 2.5% HF solution. Fig. 3 shows OCT images before (0 min) and at 15, 30, 45, 60 and 75 min after application of the corrosive. Fig. 3a shows the outcome without rinsing after chemical burn. The corneas imaged in Fig. 3b–d were rinsed for 15 min, starting 25 s after application of the acid, using tap water, 1% calcium gluconate solution and Hexafluorine<sup>®</sup>, respectively.



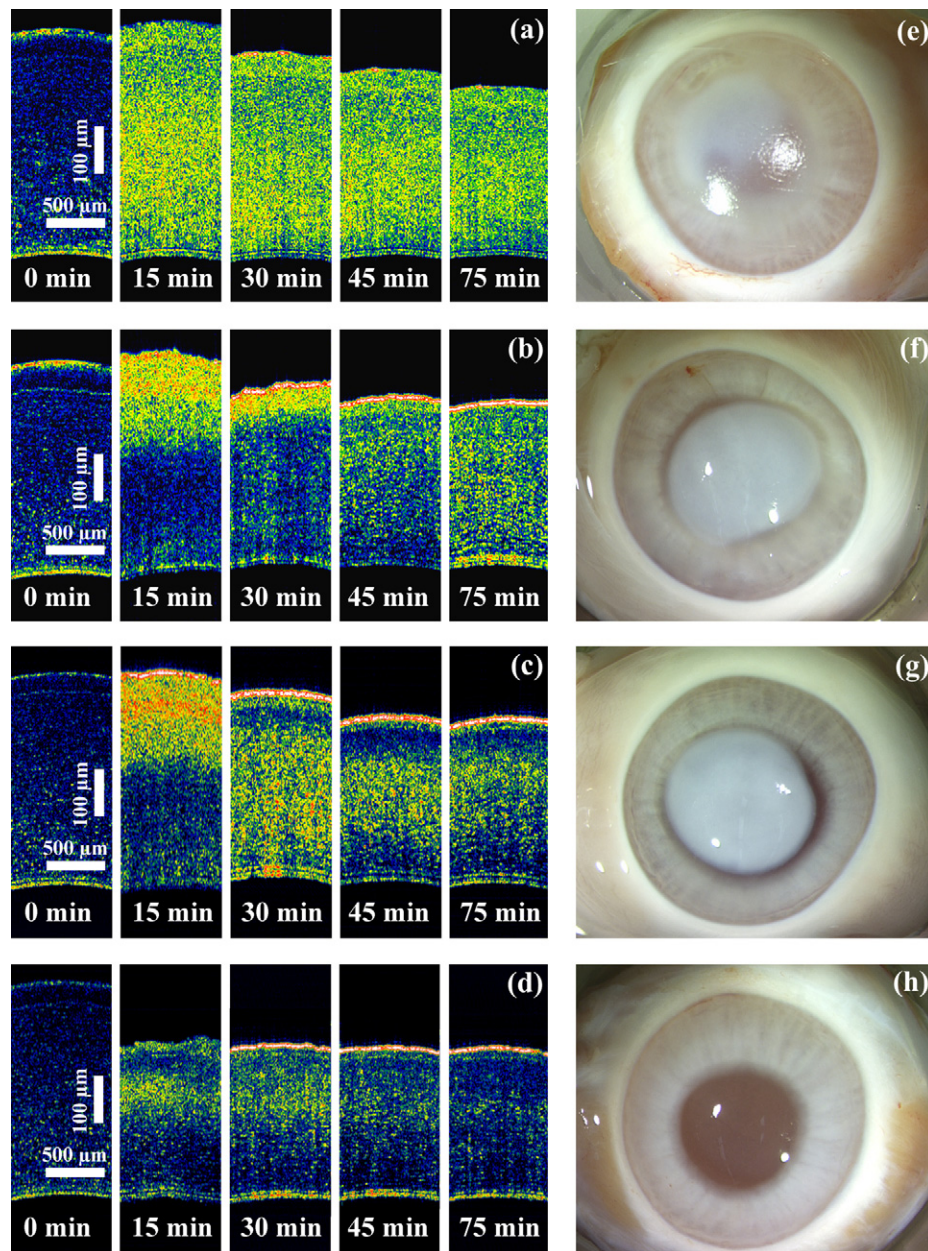
**Fig. 2 – OCT image sequence illustrating the penetration process of hydrofluoric acid (2.5%) within corneal tissue.**

The top-view photographs of the burnt corneas in Fig. 3e-h correspond to the time point of 15 min in the OCT image sequence.

The non-rinsed cornea (Fig. 3a) shows a significant increase in light scattering throughout the whole stroma after 15 min. In accordance with the dynamic analysis of HF penetration demonstrated in Fig. 2, the cornea is obviously fully penetrated by the acid. The appearance of the internal structure in OCT imaging does not change over time, but a significant decrease in corneal thickness is observed within the observation period of 75 min.

Rinsing the cornea with tap water (Fig. 3b) reduced the penetration depth to approximately half the thickness of the

cornea, measured at the end of the rinsing period (time point 15 min). Here, scattering observed within the anterior part of the cornea is higher than for the unrinsed eye. The higher opacification of the water-rinsed eye compared with the unrinsed eye also becomes apparent when comparing the top-view photographs (Fig. 3e and f) of the corneas at this time point. No conclusion can be drawn from the photographs on the depth of chemical damage. In the following 60 min, increasing opacification of the posterior part of the cornea and shrinkage of the cornea was observed; 75 min after HF application and rinsing with tap water, the cornea is fully penetrated even though the light scattering appears less intensive than in the non-rinsed cornea.

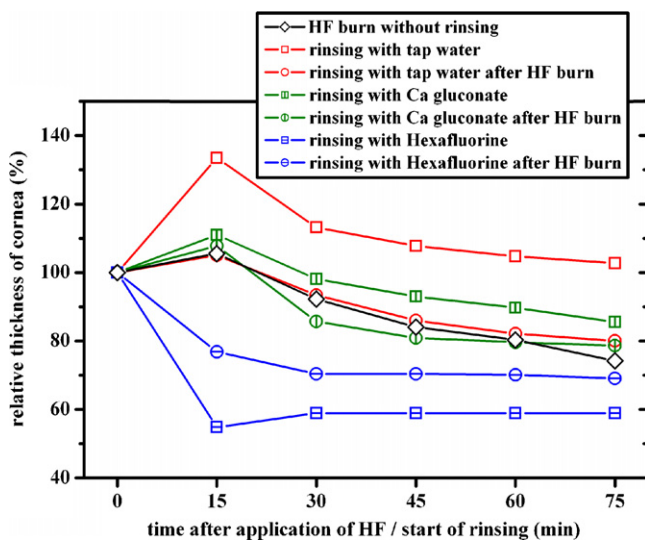


**Fig. 3** – OCT image sequences (a–d) and top-view photographs (e–h) of the globes to evaluate the efficiency of different rinsing solutions after hydrofluoric acid burn. The photographs correspond to time point 15 min of the OCT image sequences. (a and e), no rinsing; (b and f), rinsing with tap water; (c and g), rinsing with calcium gluconate 1%; (d and h), rinsing with Hexafluorine®.

Rinsing with calcium gluconate (Fig. 3c and g) shows effects comparable with rinsing with tap water. Here, the scattering intensity observed within the damaged part of the cornea 15 min after HF burn is even higher, and full corneal penetration is seen at an earlier stage when compared with rinsing with tap water. At the end of the measurement interval, it is obvious that intracorneal scattering after calcium gluconate rinsing is decreasing again with time. This observation might indicate that in this case the observed damage within the stroma is reversible to some extent. Nevertheless the cornea was fully penetrated, predicting total loss of the organ, as in the case of rinsing with tap water.

In contrast to these findings, the outcome after using Hexafluorine<sup>®</sup> as rinsing agent (Fig. 3d and h) shows that this solution is able to stop the expanding penetration of HF. Here, no increased scattering is observed in the posterior part of the stroma within a time period of 1 h after rinsing. This is confirmed by the comparatively low-scattering intensity within the anterior stroma at the end of the rinsing period, which is also documented by the top-view image of the cornea (Fig. 3h), where no opacification is observed. After the rinsing period, a substantial decrease of intracorneal scattering over time is detailed by OCT imaging.

The corneal thickness noted directly after rinsing with Hexafluorine<sup>®</sup> is about 70% of the initial thickness. In contrast to this, swelling of the healthy cornea occurs when a hypoosmolar rinsing solution, such as tap water or 1% calcium gluconate, is used. Shrinkage of the HF-burnt corneas during and after the rinsing period is found with all rinsing solutions, but additional shrinkage after the rinsing period is not observed when using hyperosmolar Hexafluorine<sup>®</sup>. Independently of treatment, the corneal thickness after HF burn is reduced within 75 min to 68–78% of the original value. This experiment gives clear indications for the inversion of the water outflow towards the epithelial site, which is part of the concept of hyperosmolar rinsing of corneal burns. Thus, ions and corrosives are transported by means of water flow out of the tissues.



**Fig. 4 – The effect of rinsing on corneal thickness for different rinsing solutions without preceding corneal burn (squares) and after hydrofluoric acid burn (dots).**

Fig. 4 summarises the changes in corneal thickness for the different treatment conditions after HF burn (dots). Additionally, effects of rinsing without preliminary treatment with HF are also shown within this graph (squares). Without prior application of HF significant swelling was observed when eyes were rinsed with water; this effect abated within 60 min after the rinsing was stopped. With calcium gluconate, a minor effect on corneal thickness was seen; and Hexafluorine<sup>®</sup> produced shrinkage of the cornea with about 40% loss of thickness. Without previous eye burn, the appearance of the corneal microstructure in OCT imaging showed no increased scattering within the cornea for any of the rinsing solutions under test (not shown).

## 4. Discussion

Knowledge is lacking regarding the dynamics of tissue trauma induced by fluoride ions, and regarding decontamination of fluoride ions from tissue. In this study, we demonstrate that OCT imaging provides substantial information about HF-induced corneal damage, which is not available when using established methods such as intracameral pH measurements. In OCT, signal amplitude correlates with the scattering cross-section of the tissue under investigation. The healthy stroma transmits 99% of the incident light without scattering. This transparency of the stroma is based on its microstructure [17]. Any changes of interfibrillar distance or of the lattice-like structure of collagen fibrils results in opacification of the stroma and therefore an increase of the OCT signal amplitude. During chemical eye burn, the microstructure of the stroma is modified by direct chemical interaction as well as by water–electrolyte imbalance, which is followed by a change of hydration state. Coagulation of proteins within the epithelium, induced by the acidic properties of the HF solution as well as by  $\text{CaF}_2$  and  $\text{MgF}_2$  precipitation, results in increased scattering. Therefore, OCT imaging allows for direct assessment of the development of the diffusion processes within the cornea, with high spatial and temporal resolution. This is demonstrated in Fig. 2, which shows that the penetration velocity of the corrosive decreases over time following HF application. The decrease can be referred to the dilution of the chemical within the tissue. This interpretation corresponds well to the observed dependence of penetration velocity on acid concentration. The direct access to the diffusion process by means of OCT measurements during exposure is an important tool for the exact definition of possible damage at different intervention time points of first aid. This will allow future definition of reversible and irreversible damage to the eye.

Clinical decontamination of HF with water and with calcium gluconate [18] is officially recommended by the American National Standards Institute and by European organisations such as the Berufsgenossenschaften in Germany [19]. In addition, Hexafluorine<sup>®</sup> may be used as a specific emergency decontamination fluid for HF burn. There are reports in the literature documenting excellent outcome after life-threatening exposures of persons to high concentrations of HF, saved by immediate rinsing with Hexafluorine<sup>®</sup> [20–22]. However, experimental studies on rat skin were not conclusive as to the advantages of Hexafluorine<sup>®</sup> compared with

calcium gluconate gel application. Two contradictory studies on Hexafluorine<sup>®</sup> use for HF-burnt skin have been published within the last 3 years [21,23]. Thus, experimental evidence for the efficacy of different treatment concepts, e.g. rinsing with calcium gluconate or with Hexafluorine<sup>®</sup>, is not yet clear.

Limited experience with earlier OCT studies, on the diffusion of sulphuric acid within the cornea, have led us to conclude that acidic diffusion processes are not as stable as assumed in the past. Corneas showed both late and early breakthrough of epithelial barriers. Such individual variations might be caused in part by detergent use before experimentation, and the contradictory results mentioned above might be due to such differences. These effects can now be controlled by means of OCT imaging which allows direct access to the diffusion process during exposure.

The OCT images representing the opacities of the corneas after HF burn with and without rinsing (Fig. 3) demonstrate that immediate rinsing after HF eye burn can significantly reduce corneal damage. OCT images recorded directly after the rinsing period (15 min after chemical burn) show that all rinsing solutions under test are able to limit the structural damage to the anterior half of the cornea, whereas there was full corneal penetration of the unrinsed eye at this time point. This is also true for rinsing with water and rinsing with calcium gluconate solution; in both cases, increased opacification compared with an unrinsed eye is seen in the top-view photographic images. An evident dependence of decontamination power on the rinsing solution is observed at later time points; a late total increase in scattering intensity within the middle and deep stroma is found for rinsing with tap water (Fig. 3b) or with calcium gluconate (Fig. 3c), indicating ongoing damage. This might be the result of formation of insoluble precipitates (CaF<sub>2</sub>), which could also explain the acute increase in scattering within the anterior cornea when calcium gluconate solution is used for rinsing.

The findings for tap water and calcium gluconate are in clear contrast to the almost complete decontamination achieved by Hexafluorine<sup>®</sup>, with low intracorneal OCT signal after 15 min (Fig. 3d). The status of the cornea, based on intracorneal scattering, shows slight improvement within 1 h after the end of rinsing. This indicates that Hexafluorine<sup>®</sup> effectively prevents ongoing damage and further penetration. Thus, there is clear evidence, when comparing the result with the appearance of the other rinsed eye HF burns, that Hexafluorine<sup>®</sup> is an effective antidote in first aid treatment to prevent further tissue damage, and that water rinsing is the least effective treatment. Hexafluorine<sup>®</sup> is therefore our primary candidate for systematic decontamination studies.

Our experiments also demonstrated that the fluid exchange of the cornea depends on the osmolarity of the rinsing solutions used [24]. The appropriateness of the EVEIT system can be shown by the reversal of swelling of the water-rinsed healthy cornea after 75 min, to normal thickness (Fig. 4). This verifies the efficacy of the endothelial action in dehydration of the corneal stroma. Hexafluorine<sup>®</sup>, as a hyperosmolar agent, is able to reverse water flow from the stroma towards the corneal surface, and this results in a considerable decrease of corneal thickness through the semipermeable corneal epithelium [25]. This dehydration is stable; the cornea remains clear, and no damage due to the

hyperosmolarity of Hexafluorine<sup>®</sup> can be observed. In case of HF burn, the cornea is strongly dehydrated in all cases with and without rinsing therapy. This indicates a structural change in the ground substance with a major loss of water and water-binding capacity from the burnt corneal tissue. An explanation for this finding might be the complete loss of free calcium within the tissue and shrinkage of the proteins that are involved in the hydration system, by liberated hydrogen with acidic protein coagulation in the HF-burnt cornea. The inversion by means of hyperosmolar rinsing of the burnt eye with Hexafluorine<sup>®</sup> is shown to be effective by physical inversion of water flow characteristics and chemical neutralisation of H<sup>+</sup> and F<sup>-</sup> ions, the Hexafluorine<sup>®</sup>-rinsed cornea remaining clear for 75 min after burning (Fig. 3).

## 5. Conclusion

In summary, OCT as an additional diagnostic tool within the EVEIT system is able to enhance the information made available by this test method. The direct access to the diffusion process of HF into the cornea allows for the quantification of therapy strategies with new substances such as Hexafluorine<sup>®</sup>, and comparison with established rinsing solutions such as calcium gluconate or water, with a reduced number of tests. The combination of methods described warrants further chemical product testing, without research on living animals and within the REACH initiative, a new regulatory framework issued by the European Union.

## Acknowledgements

This investigation was partially supported by Prevor, manufacturers of Hexafluorine<sup>®</sup>, who financed the rinsing solutions and other materials but did not otherwise influence the study. Personal costs and equipment were financed by the Aachen Centre of Technology Transfer in Ophthalmology and by the Institute of Semiconductor Electronics of the RWTH Aachen University. Prevor required evaluation of the applicability of their product in the special case of HF burns.

## REFERENCES

- [1] McCulley J. Ocular hydrofluoric acid burns. Animal model, mechanism of injury and therapy. *Trans Am Ophthalmol Soc* 1990;88:649-84.
- [2] Schrage NF, Frenzt M, Nietgen A, Langefeld S, Reim M. Corneal calcification related to phosphate buffer. The Ex Vivo Eye Irritation Test (EVEIT) as predictor of risk. *Graefes Arch Clin Exp Ophthalmol*, submitted.
- [3] Huang D, Swanson EA, Lin CP, Schuman JS, Stinson WG, Chang W, et al. Optical coherence tomography. *Science* 1991;254:1178-81.
- [4] Izatt JA, Hee MR, Swanson EA, Lin CP, Huang D, Schuman JS, et al. Micrometer-scale resolution imaging of the anterior eye in vivo with optical coherence tomography. *Arch Ophthalmol* 1994;112:1584-9.
- [5] Reiser BJ, Ignacio TS, Wang Y, Taban M, Graff JM, Sweet P, et al. In vitro measurement of rabbit corneal epithelial

- thickness using ultrahigh resolution optical coherence tomography. *Vet Ophthalmol* 2005;8:85-8.
- [6] Grieve K, Paques M, Dubois A, Sahel J, Boccara C, Gargasson J-FL. Ocular tissue imaging using ultrahigh-resolution, full-field optical coherence tomography. *Invest Ophthalmol Vis Sci* 2004;45:4126-31.
- [7] Drexler W. Ultrahigh-resolution optical coherence tomography. *J Biomed Opt* 2004;9:47-74.
- [8] Yeh AT, Kao B, Jung WG, Chen Z, Nelson JS, Tromberg BJ. Imaging wound healing using optical coherence tomography and multiphoton microscopy in an in vitro skin-equivalent tissue model. *J Biomed Opt* 2004;9:248-53.
- [9] Hosseini K, Kholodnykh AI, Petrova IY, Esenaliev RO, Hendrikse F, Motamedi M. Monitoring of rabbit cornea response to dehydration stress by optical coherence tomography. *Invest Ophthalmol Vis Sci* 2004;45:2555-62.
- [10] Wang J, Simpson TL, Fonn D. Objective measurements of corneal light-backscatter during corneal swelling, by optical coherence tomography. *Invest Ophthalmol Vis Sci* 2004;45:3493-8.
- [11] Ghosn MG, Tuchin VV, Larin KV. Depth-resolved monitoring of glucose diffusion in tissues by using optical coherence tomography. *Opt Lett* 2006;31:2314-6.
- [12] Spöler F, Först M, Marquardt Y, Hoeller D, Kurz H, Merk H, et al. High-resolution optical coherence tomography as a non-destructive monitoring tool for the engineering of skin equivalents. *Skin Res Technol* 2006;12:261-7.
- [13] Rihawi S, Frentz M, Schrage NF. Emergency treatment of eye burns: which rinsing solution should we choose? *Graefes Arch Clin Exp Ophthalmol* 2006;244:845-54.
- [14] Fercher AF, Drexler W, Hitzengerger CK, Lasser T. Optical coherence tomography principles and applications. *Rep Prog Phys* 2003;66:239-303.
- [15] Welzel J. Optical coherence tomography in dermatology: a review. *Skin Res Technol* 2001;7:1-9.
- [16] Drexler W, Hitzengerger CK, Baumgartner A, Findl O, Sattmann H, Fercher AF. Investigation of dispersion effects in ocular media by multiple wavelength partial coherence interferometry. *Exp Eye Res* 1998;66:25-33.
- [17] Hart RW, Farrell RA. Light scattering in the cornea. *J Opt Soc Am* 1969;59:766-74.
- [18] Beiran I, Miller B, Bentur Y. The efficacy of calcium gluconate in ocular hydrofluoric acid burns. *Hum Exp Toxicol* 1997;16:223-8.
- [19] Emergency procedure guide-Transport-Hydrofluoric acid, Standards Australia, Standard No. AS 1678.8.0.008, ISBN 0 7337 22768 8, 1998.
- [20] Dunser MW, Ohlbauer M, Rieder J. Critical care management of major hydrofluoric acid burns: a case report, review of the literature, and recommendations for therapy. *Burns* 2004;30:391-8.
- [21] Mathieu L, Nehles J, Blomet J, Hall AH. Efficacy of hexafluorine for emergent decontamination of hydrofluoric acid eye and skin splashes. *Vet Hum Toxicol* 2001;43:263-5.
- [22] Hall AH, Soderberg K, Kuusinen P, Mathieu L. An improved method for emergent decontamination of ocular and dermal hydrofluoric acid splashes. *Vet Hum Toxicol* 2004;46:216-8.
- [23] Hojer J, Personne M, Hulten P, Ludwigs U. Topical treatments for hydrofluoric acid burns: a blind controlled experimental study. *J Toxicol Clin Toxicol* 2002;40:861-6.
- [24] Kompa S, Schareck B, Tympner J, Wüstemeyer H, Schrage NF. Comparison of emergency eye-wash products in burned porcine eyes. *Graefes Arch Clin Exp Ophthalmol* 2002;240:308-13.
- [25] Kompa S, Redbrake C, Hilgers C, Wüstemeyer H, Schrage N, Remky A. Effect of different irrigating solutions on aqueous humour pH changes, intraocular pressure and histological findings after induced alkali burns. *Acta Ophthalmol Scand* 2005;83:467-70.