

SERUM PRO-INFLAMMATORY CYTOKINES AND CHEMICAL ACID BURNS IN RATS

Cavallini M.,¹ de Boccard F.,² Corsi M.M.,² Fassati L.R.,³ Baruffaldi Preis F.W.¹

¹ Unit of Plastic Surgery, Galeazzi Hospital, Milan, Italy

² Laboratory of Clinical Pathology, Institute of General Pathology, University of Milan, Milan

³ Institute of Experimental Surgery, University of Milan

SUMMARY. This experimental study measures the evolution of the concentration of interleukin-6 and the tumour necrosis factor α in rats, after a chemical burn with hydrochloric acid (0.5 ml, 52% for 15 sec), comparing the results between saline solution, calcium gluconate, and an amphoteric solution called Diphoterine®.

Introduction

After chemical burns many products are used in clinical practice to wash the damaged skin.¹

In this study we compare the effects on wound healing and immunological responses of saline solution (0.9%), calcium gluconate, and an amphoteric solution (Diphoterine®) after burns on rats induced by hydrochloric acid (0.5 ml, 52% for 15 sec.²

Diphoterine®, an amphoteric rinse, is used in the emergency treatment of serious ocular burns.^{3,4}

In this particular case we studied the plasma level of two inflammatory cytokines, interleukin-6 (IL-6) and the tumour necrosis factor α (TNF- α), which have been shown to induce production of a series of acute phase proteins.

TNF- α is an activator of the vascular endothelium that provokes an enhancement of permeability, with systemic effects such as fever and shock.⁵ TNF- α also increases lymphatic drainage. IL-6 activates the lymphocytes in acute inflammation and is an important cytokine in the production of the protein in the acute phase.⁶

Acids are entities that can release H⁺ ions or fix OH⁻ ions.

When many H⁺ ions come into contact with the skin, penetration happens quickly through the inter- and intracellular space. We can observe the direct effect on the cell membrane, where the cell membrane breaks and the cells burst.⁷ The interruption of the osmotic balance plays an important role, but the breaking and the crossing of the H⁺ ions are not always systematic. Inside the tissues, the H⁺ ions will react essentially with the proteins and produce irreversible structural changes.⁸ These changes are reflected in the coagulation phenomenon, and come at the same time as heat production. This phenomenon provokes

the cell's death, with a high level of cytokines. Cytokines are immunoregulatory proteins and glycoproteins that go through specific receptors on target cells in a paracrine, autocrine, or endocrine manner.⁹ These molecules are produced by a variety of cells, including those of the epidermis, and include interleukins, TNFs, and others. Cytokines are involved in the differentiation, activation, and proliferation of both immune and non-immune cells involved in immuno-inflammatory reactions.

Materials and methods

We took 20 male Sprague-Dawley CD rats (250 to 300 g), which received a standardized burn with 52% hydrochloric acid (0.5 ml) for 15 sec. The cutaneous area was prepared beforehand by shaving the skin over the scapula-humeral articulation.

The animals were anaesthetized with 30 mg/kg ketamine. All procedures involving animals and their care were conducted in conformity with Institutional Guidelines in compliance with National (Italian Law Decree no. 116, Official Gazette Suppl. 40, 18 Feb. 1992) and International Laws and Policies (EC Council Directive 86/609, OJL 358, 1, 12 Dec. 1987; NIH Guide for the Care and Use of Laboratory Animals, NIH Publication No. 85-23, 1985).

The burned rats were divided into four treatment groups.

Group 1 animals received no treatment. Group 2 animals were washed with saline solution (0.9% NaCl), group 3 animals with calcium gluconate, and group 4 animals with Diphoterine®. The wash lasted 30 sec.

Blood samples for measurement of plasma levels of IL-6 and TNF- α were taken at different moments - after 6 h, 48 h, and 7 days. The samples were taken from the caudal vein using a butterfly needle.

Cytokine assays

For IL-6, the assay uses the quantitative sandwich enzyme immunoassay technique (R&D System Inc., MN, USA). A monoclonal antibody specific for rat IL-6 is pre-coated onto a microplate. Standards, controls, and samples are pipetted into the wells and any rat IL-6 present is bound by the immobilized antibody. After washing away any unbound substances, an enzyme-linked polyclonal antibody specific for rat IL-6 is added to the wells. Following a wash to remove any unbound antibody-enzyme reagent, a substrate solution is added to the wells. The enzyme reaction yields a blue product that turns yellow when the stop solution is added. The intensity of the colour measured is in proportion to the amount of rat IL-6 bound in the initial step. The sample values are then read off the standard curve.

For the TNF- α assay (R&D System Inc., MN, USA), the technique used was exactly the same as for IL-6, except naturally for the antibodies and standards.

Statistical methods

The differences between data were studied using analysis of variance (ANOVA) and Bartlett's test. Tukey's multiple comparison test was applied as needed. Statistical significance was taken as $p < 0.05$.

Results are shown as the mean \pm standard deviation.

Results

The results of the plasma assays for the immunological parameters are shown in Figs. 1 and 2.

Regarding TNF- α (Fig. 1), there was a decrease of

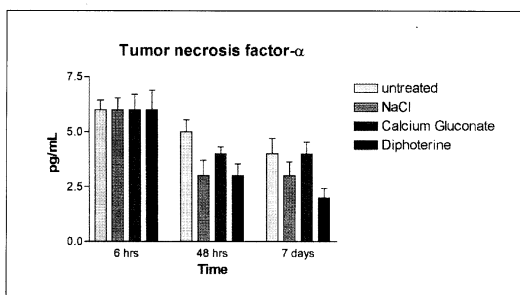


Fig. 1 - Tumour necrosis factor- α .

this cytokine after 6 h, 48 h, and 7 days in all of the treatments, but there was no significant difference between the single treatment at the different times (6 h, 48 h, and 7 days).

For IL-6 (Fig. 2), the acute phase protein, there was, as with TNF- α , a decrease of the cytokine at the different periods. Unlike TNF- α , for IL-6 there were significant differences between the different treatments.

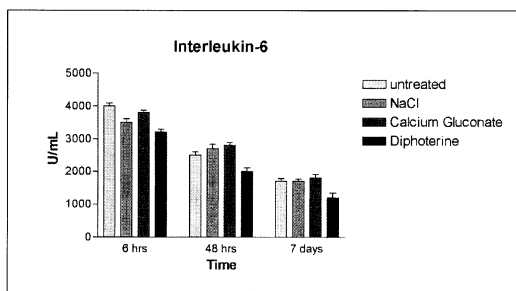


Fig. 2 - Interleukin-6.

At 6 h we can see Untreated vs NaCl with $p < 0.01$. NaCl was diminished; Untreated vs Diphoterine[®] and calcium gluconate vs Diphoterine[®] with $p < 0.001$ considered extremely significant. In both, Diphoterine[®] was diminished.

At 48 h we have Untreated vs Diphoterine[®] with $p < 0.05$; NaCl vs Diphoterine[®] with $p < 0.01$ and calcium gluconate vs Diphoterine[®] with $p < 0.001$. In both, Diphoterine[®] was diminished.

At 7 days we observe Untreated vs Diphoterine[®] with $p < 0.05$; NaCl vs Diphoterine[®] with $p < 0.05$ and calcium gluconate vs Diphoterine[®] with $p < 0.01$. In both, Diphoterine[®] was diminished.

Discussion

IL-6 and TNF- α production is enhanced during inflammation and following burns.³ In this study, the use of Diphoterine[®] was associated with decreased plasma levels of these parameters at 6 h, 48 h, and 7 days after experimental hydrochloric acid skin burns, as compared to untreated controls and following decontamination with either normal saline or 10% calcium gluconate solution. We suggest that a decrease in IL-6 serum levels could better explain the continued good health of the rats burned with hydrochloric acid throughout the treatment. We can affirm that Diphoterine[®] works as well as calcium gluconate, in the modulation of IL-6 serum levels. Our data suggest that Diphoterine[®] can in part modulate inflammatory promoters by limiting the enhancement of IL-6, an important inducer of the acute phase during inflammation.⁶

Contact with hydrochloric acid for 15 sec caused a deep burn of 20 mm on the back of the rats, showing the final result after 24 h. The rats were washed with three differ-

ent solutions, and one group was untreated. The rats that were locally untreated were covered only with sterile gauze.

After 48 h we saw no particular differences in wound healing in all the treated groups.

After 7 days we noted the following results:

* The untreated group still showed a deep burn of 12 mm with the presence of necrotic tissue and an inflammatory area around the wound.

* The group treated with calcium gluconate showed a residual burned area of 9 mm with a central presence of necrotic tissue.

* The groups treated with NaCl solution (Fig. 3) and Diphoterine® (Fig. 4) showed the best results: there was a considerable contraction, with a residual burned zone of 5 mm, with the presence of central tissues showing progressive and spontaneous re-epithelialization. The Diphoterine®-treated group showed better re-epithelialization than the NaCl group, with a residual wound of 4 mm for Diphoterine® vs 6 mm for NaCl.

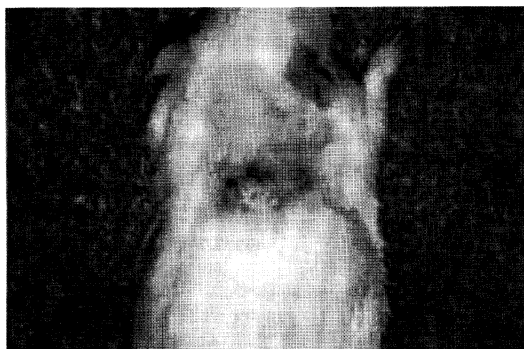

Fig. 3 - Burned rat treated with NaCl after 7 days.

Improved wound healing in the Diphoterine® decontamination group compared with undecontaminated controls or animals decontaminated with either normal saline or 10% calcium gluconate was evidenced by a more rapid resolution of the necrotic area and better healing of the burned tissue, starting from the external margin of the burn.

Conclusion

Decontamination with Diphoterine® modulated the pro-inflammatory plasma cytokine IL-6 in this experimental hydrochloric acid dermal burns model and promoted better wound healing compared with non-decontamination or decontamination with either normal saline or 10% calcium gluconate solution.

Our results suggest that Diphoterine® could be a more effective means of active decontamination of acid dermal splashes.

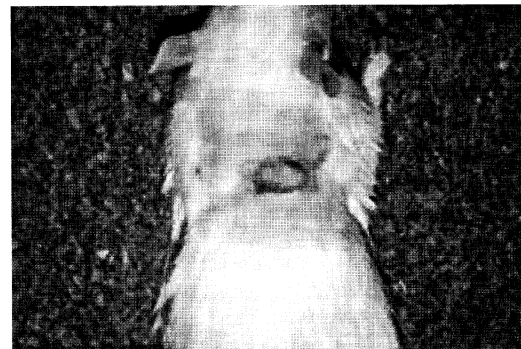


Fig. 4 - Burned rat treated with Diphoterine® after 7 days.

RÉSUMÉ. Cette étude expérimentale considère l'évolution des mesures de concentration de l'interleukine-6 et le facteur de nécrose de la tumeur α dans le rat, après une brûlure chimique avec acide chlorhydrique (0,5 ml, 52% pendant 15 sec), et présente une comparaison des résultats avec une solution saline, le gluconate de calcium et une solution amphotérique appelée Diphoterine®.

BIBLIOGRAPHY

1. Beiran I., Miller B., Bentur Y.: The efficacy of calcium gluconate in ocular hydrofluoric acid burns. *Human and Experimental Toxicology*, 16: 223-8, 1997.
2. Hojer J., Personne M., Hulten P., Ludwigs U.: Topical treatment for hydrofluoric acid burns. A blind controlled experimental study. *J. Clin. Toxicol.*, 40: 861-6, 2003.
3. Gerard M., Merle H., Chiambretta F., Rigal D., Schrage N.F.: An amphoteric rinse used in the emergency treatment of a serious ocular burn. *Burns*, 28: 670-3, 2002.
4. Schrage N.F., Kompa S., Haller W., Langefeld S.: Use of an amphoteric lavage solution for emergency treatment of eye burns. First animal experimental clinical considerations. *Burns*, 28: 782-6, 2002.
5. Caldwell F.T., jr, Graves D.B., Wallace B.H.: Pathogenesis of fever in a rat burn model: The role of cytokines and lipopolysaccharide. *J. Burn Care Rehabil.*, 186: 525-30, 1997.
6. Van Gool J., van Vugt H., Helle M., Aarden L.A.: The relation among stress adrenalin interleukin-6 and acute phase proteins in the rat. *Clin. Immunology Immunopathology*, 57: 200-10, 1990.
7. Kirkpatrick J.J.R., Burd D.A.R.: An algorithmic approach to the treatment of hydrofluoric acid burns. *Burns*, 21: 495-9, 1995.

8. Kirkpatrick J.J.R., Enion D.S., Burd D.A.R.: Hydrofluoric acid burns: A review. *Burns*, 21: 483, 1995.
9. Ohzato H., Monden M., Yoshizaki K., Ogata A., Nishimoto N., Gotoh M., Kishimoto T., Mori T.: Systemic production of IL-6 following acute inflammation. *Biochemical and Biophysical Research Communications*, 197: 1556-62, 1993.

This paper was received on 12 January 2004.

Address correspondence to: Dr M. Cavallini, Unit of Plastic Surgery, Viale Lombardia 18, 20131 Milan, Italy.
Tel.: 390270638009; e-mail: maurizio.cavallini@libero.it